



PATIENT

Roxy Jankola

SPECIES

Canine

BREED

Chihuahua

SEX

Female Spayed

AGE

11.3 years

WEIGHT

4.7lbs

INTERPRETED BY

Maggie Machen Lamy,
DVM, DACVIM
(Cardiology)

IMAGING PERFORMED BY

Brian Barnes, DVM

HOSPITAL NAME

Westview Veterinary
Hospital

REFERRING VET

Dr. Barnes

INVOICE

24888

DATE

6/21/22

PRESENTING CLINICAL SIGNS

History: Cardiac murmur grade 2-3/6, PMI left hemithorax noted June 2021. Now grade 4/6. History of syncope when barking, hot, panting, or choking, 3x on walk recently.

-Abnormal PE/Chem/CBC/UA Results: CBC: WNL besides, mild increase platelets 551 (143-448)

CHEM: WNL besides mild increase SDMA 15 (0-14), ProBNP 4437 (0-900), TT4 WNL.

-Radiographs: Moderate cardiomegaly; severe tracheal and mainstem bronchial collapse.

-BP: 156mmHg

ECHOCARDIOGRAM FINDINGS

2D, m-mode, color flow and doppler imaging is available. Diffuse thickening of mitral valve leaflets (anterior>posterior) with mild prolapse into the left atrial lumen. Moderate eccentric mitral regurgitation with moderate left atrial dilation. Normal MR velocity. No significant LV diameter with adequate myocardial function. The tricuspid valve appears thickened with septal prolapse and moderate tricuspid regurgitation. Normal velocity. Normal right atrial and ventricular diameter. The pulmonic and aortic valves are normal in morphology and mobility. Normal pulmonic and aortic outflow velocities. Trace aortic and pulmonic insufficiency. No pericardial or pleural effusion noted. No cardiac tumors observed.

CARDIAC CHART

CANINE CARDIAC PARAMETERS	MR VMAX (m/s)	TR VMAX (m/s)	LA/AO (Boon method)	LA/AO (Heart Base; Swe)	FS (%)	EF (%)	EPSS (cm)
NORMAL PARAMETER	4.5-5.5	<2.7	1.3	<1.6	28-40	40-100	<0.6
PATIENT	4.8	2.7	1.4	1.75	57	89y	NM
CANINE CARDIAC PARAMETERS	HR (BPM)	AV VMAX (m/s)	PV MAX (m/s)	BODY WEIGHT (kg)	LA 2D short axis Base view (cm)	LVIDd Avg; 2D and m-mode short axis (cm)	LVIDs Avg; 2D and m-mode short axis (cm)
NORMAL PARAMETER	50-100	0.7-1.7	0.7-1.6	BELOW	BELOW	BELOW	BELOW
PATIENT		1.3	0.77	2.12	1.75	2.3	1.0
*Normal chamber parameters expressed as a mean value (SD)				3	1.27 (5.3)	2.46 (2.46)	1.36 (5.5)
BODY WEIGHT DEPENDENT PARAMETERS				5	1.40 (4.5)	2.74 (5.2)	1.60 (4.7)
<i>*Note: All measurements based upon multi-modal images and methods. An average value is reported.</i>				10	1.50 (3.8)	3.27 (3.5)	2.06 (3.1)
				15	1.83 (2.0)	3.71 (2.4)	2.43 (2.1)
				20	2.02 (1.9)	4.14 (2.2)	2.80 (2.0)
				25	2.18 (2.4)	4.48 (2.9)	3.10 (2.5)
				30	2.33 (3.3)	4.83 (3.9)	3.39 (3.4)
				35	2.48 (4.3)	5.17 (5.0)	3.69 (4.5)
				40	2.62 (5.2)	5.48 (6.1)	3.96 (5.4)
				50	2.88 (7.1)	6.07 (8.3)	4.46 (7.4)

INTERPRETATION OF THE FINDINGS & FURTHER RECOMMENDATIONS

Chronic degenerative valve disease causing moderate mitral and tricuspid regurgitation. Moderate left atrial enlargement indicates there is relatively low risk for imminent complication, however risk for progression to spontaneous congestive heart failure in the future is elevated. A small aortic leak is noted; however, reported BP is reasonable. No additional issues are identified.



PATIENT

Roxy Jankola

Given the risk for progression and results of the EPIC trial, Pimobendan is indicated in this patient as below. Assessment of progression in the future will help predict long term outcome; however, prognosis is guarded at this stage (B2).

SPECIES

Canine

While mainstem bronchi compression may certainly be contributing to a chronic increase in coughing, other primary airway contributions should also be considered based upon the CXR report (tracheal collapse, COPD/chronic bronchitis, etc). Consider hydrocodone for any mechanical component due to cardiomegaly.

BREED

Chihuahua

No definitive cardiac cause for the episodes is seen in this study (i.e. no significant PAH, no obvious rupture or tears, reasonable cardiac output, etc.) and other causes should be considered. These possible causes include vasovagal events, intermittent arrhythmias, neurologic/systemic issues, etc. That being said, if the episodes are consistently occurring with significant exertion there certainly is a possibility that regurgitant volume is involved and Pimobendan may help. An intermittent arrhythmia cannot be ruled out without a Holter monitor, and this should be considered if episodes continue undiagnosed. Further systemic evaluation may also be considered including AUS.

SEX

Female Spayed

Omega fatty acid supplementation and mild salt restriction may also be of some long term benefit. Monitor for development of a progressive cough, labored breathing, exercise intolerance or collapse episodes.

AGE

11.3 years

WEIGHT

4.7lbs

Once on the medication for 3-5 days, anesthetic risk is considered mildly elevated. Cardiac protective drug choices (opioid/benzodiazepine premedication, Propofol or alfaxalone induction, iso or sevo gas) are recommended. Monitor for arrhythmias, hypotension, and hypoxia both intra and post-operatively and intervene as necessary. Judicious IV fluid rates are recommended to avoid fluid overload. Avoid heart rate stimulating drugs such as atropine unless clinically indicated.

INTERPRETED BY

Maggie Machen Lamy,
DVM, DACVIM
(Cardiology)

Plan: Institute heart muscle support Pimobendan 0.3mg/kg PO q12h. Consider hydrocodone as discussed.

IMAGING PERFORMED BY

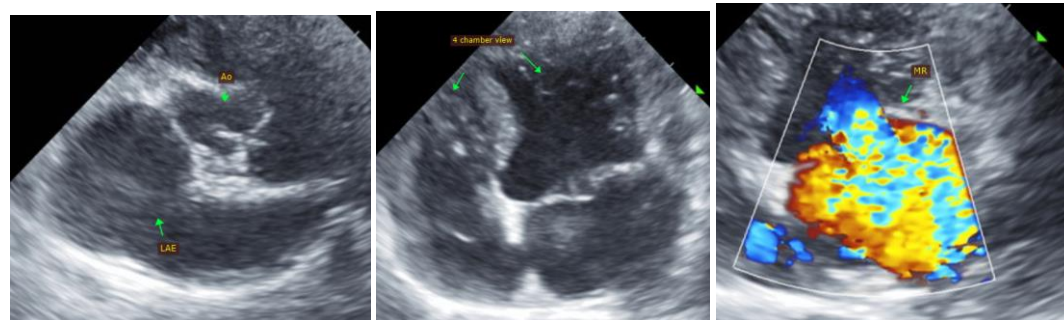
Brian Barnes, DVM

Recommend monitor for progression with a recheck echocardiogram in 6 months, sooner if any development of clinical signs.

HOSPITAL NAME

Westview Veterinary
Hospital

IMAGES



REFERRING VET

Dr. Barnes

The information and recommendations provided are based on the images presented by the referring veterinarian. No evaluation can be communicated regarding pathology that was not visible in the image/video clips provided.

INVOICE

24888

DATE

6/21/22

Thank you for this referral. This report was generated using transcription software, and minor dictation errors may be present. If the clinical or image interpretation does not parallel your findings



PATIENT

Roxy Jankola

SPECIES

Canine

BREED

Chihuahua

SEX

Female Spayed

AGE

11.3 years

WEIGHT

4.7lbs

INTERPRETED BY

Maggie Machen Lamy,
DVM, DACVIM
(Cardiology)

**IMAGING
PERFORMED BY**

Brian Barnes, DVM

HOSPITAL NAME

Westview Veterinary
Hospital

REFERRING VET

Dr. Barnes

INVOICE

24888

DATE

6/21/22

or if I can be of any further assistance, please contact me.

Maggie Machen Lamy, DVM
Diplomate of the American College of Veterinary Internal Medicine (Cardiology)
info@sonopath.com